



Symptomatic Papillary Fibroelastoma- Case Report and Literature Review

**Saurabh Joshi^{1*}, Aditi Ahlawat², Alireza Hosseinneshad¹, Mark Kranis³,
Joshua Greenberg³ and Robert M. Bojar⁴**

¹*Department of Medicine, St Vincent Hospital, University of Massachusetts Medical School,
Worcester, Massachusetts, USA.*

²*University of Massachusetts Medical School, Worcester, Massachusetts, USA.*

³*Division of Cardiology, St Vincent Hospital, Worcester, Massachusetts, USA.*

⁴*Division of Cardiothoracic Surgery, St Vincent Hospital, Worcester, Massachusetts, USA.*

Authors' contributions

This work was carried out in collaboration between all authors. Authors SJ and AH wrote the manuscript and did the literature search. Author AA helped with the initial draft of the manuscript. Author MK, edited initial and final drafts of manuscript and acquired and reviewed images for manuscript. Authors JG and RMB participated in editing of manuscript and supervision of case. All authors read and approved the final manuscript.

Article Information

DOI: 10.9734/BJMMR/2015/17608

Editor(s):

(1) E. Umit Bagriacik, Department of Immunology, Gazi University, Turkey.

Reviewers:

(1) Rodrigo Crespo Mosca, Energetic and Nuclear Research Institute (IPEN/CNEN – SP), CTR - Radiation Technology Center, São Paulo University (USP), Brazil.

(2) Anonymous, Dicle University, Turkey.

Complete Peer review History: <http://www.sciencedomain.org/review-history.php?iid=1121&id=12&aid=9355>

Review Article

Received 20th March 2015
Accepted 28th April 2015
Published 23rd May 2015

ABSTRACT

Primary cardiac tumors represent a small subset of cardiac neoplasms. The papillary fibroelastoma (PFE) is a benign tumor that typically affects the cardiac valvular system and is second in prevalence only to myxomas. Though typically asymptomatic and diagnosed incidentally, few patients with PFE may also experience neurologic and cardiac symptoms that prompt further diagnostic investigation. We present a case of a patient with transient monocular vision loss with a later occurrence of bilateral lower extremity weakness and confusion over a short period of time. The alarming symptomatology eventually led to diagnosis by transesophageal echocardiogram of a PFE involving the aortic valve. We include a review of the current literature on PFE to further

*Corresponding author: Email: sjoshi24@gmail.com;

elucidate etiology of this neoplasm, symptomology, prognosis, and treatment. Currently, the role of anticoagulation in PFE remains unclear. Due to the embolic nature of this neoplasm as evidenced by the case presentation, surgical resection, anticoagulation or a combination of both provides patients with maximal prevention of stroke.

Keywords: *Papillary fibroelastoma; embolic phenomenon; echocardiography; surgical excision; anticoagulation.*

1. SYSTEMATIC REVIEW

Primary cardiac tumors (PCT) are rare and cardiac tumors are predominantly metastatic. The incidence of PCTs is 0.021% and 0.019% on autopsy and echocardiographic series respectively [1,2]. After myxomas, the papillary fibroelastoma (PFE) is the second most common PCT with an incidence of 4.4 to 8% [3,4]. The incidence is similar between males and females (55-58% and 53.9% respectively) [5], and the mean age of diagnosis is 56-60 years with the highest prevalence in the eighth decade of life [5,6,7].

Although PFEs are believed to be neoplastic in nature, some do consider other possibilities such as hamartomas, organized thrombi, or inflammatory foci to characterize the histology of the tumor. In the literature, endothelial injury has been described as one of the most common underlying factors, as the PFE occurs mostly in patients with rheumatic heart disease, hypertrophic cardiomyopathy, prior cardiac surgery, and intervention or mantle field radiation [8,9].

PFEs are found on the left side of the heart [7]. The tumor has a predilection for valves, making this neoplasm the most common cardiac valve tumor (60-84% of the tumors are located on valves) [2,7]. The Aortic valve is most commonly involved, followed by the mitral valve (44-52% and 35-40% respectively) [7,10]. In the case of semilunar valves, the frequency for the ventricular and atrial location is equal, whereas the atrial side is favored in the case of atrioventricular valves.

PFEs is most often diagnosed incidentally and are asymptomatic. Symptomatic PFEs usually present with embolic phenomena and neurological symptoms (35% of PFE) [2]. Embolic phenomena can occur in two possible ways. First, the tumor can fragment directly given the fragile nature of the papillary fronds of the tumor. Second, the PFE can potentially act as a nidus for thrombus formation leading to

embolization. Manifestations can be serious and life threatening including stroke which encompasses transient ischemic attacks, as well as acute coronary syndrome, renal infarction, and mesenteric or limb ischemia [2,5,11]. Acute coronary syndrome can occur by either embolization or through the direct obstruction of the coronary ostia [12]. A few cases of pulmonary emboli due to right sided PFE have been reported as well.

PFE is diagnosed by imaging and are subsequently confirmed on histopathology. Transesophageal echocardiography (TEE) can detect these tumors at higher rates as compared to the transthoracic echocardiography (TTE) [9,13]. Although computed tomography (CT) is considered superior to echocardiography [13], MRI is the gold standard imaging modality when it comes to characterization of intra-cardiac masses [14]. However, echocardiography can identify most PFEs and is therefore an adequate tool for diagnosis in most cases [9]. On imaging, the PFE is characterized as a round, mobile, oval or irregular, well demarcated, homogenous, and pedunculated mass, having a speckled appearance and a stippled pattern at the edges [9,15]. On gross examination, because of its frond-like projections, it resembles a sea anemone when submerged in water [15,16]. Histologically, the tumor has a single layer of endothelial cells and papillary fronds. The matrix contains fibro elastic connective tissue, smooth muscle cells, and rarely spindle cells [7,13].

Surgical excision is the treatment of choice for symptomatic PFEs [7,9,17]. For asymptomatic large and mobile PFEs, surgical excision should be considered given the potential of severe embolic complications. Small and non-pedunculated asymptomatic PFEs can be observed with close follow-up [7]. However evidence has shown that surgical excision should be considered for these smaller tumors as well if there are no major contraindications [16,18,19]. This is because even very small PFEs have been reported to cause stroke [19]. When excision is considered, the shave excision method is

sufficient as recurrence has rarely been reported and it spares the affected valve without need of repair [5,7,10,20]. Surgical excision is usually well tolerated and curative. If valve damage is encountered, repair or replacement should be conducted [16,18]. Furthermore, the role of anticoagulation for these patients is unclear. Given the embolic nature of the tumor and the possibility of thrombus formation, some experts recommend to begin anticoagulation, most importantly for those who are not candidates for surgical excision [7,13].

2. CASE PRESENTATION

An 83-year-old woman with a past medical history of hyperlipidemia presented with two episodes of painless transient visual loss in her right eye. Each episode lasted for ten seconds and her vision returned promptly with no residual visual deficits. The patient underwent extensive work up for these episodes including a carotid artery duplex scan and head CT, both of which were unremarkable. TTE was significant for a well-circumscribed echogenic density in the lateral wall of the right atrium (Fig. 1). A follow-up TEE was scheduled for further visualization of this density. During preparation for her TEE, the patient received topical anesthetic applied to her pharynx. Within five minutes of application of anesthetic, she suddenly became confused, had

significant difficulty speaking in coherent sentences and could not follow simple commands. In addition, she developed a bilateral lower extremity paresis. Specifically, she could not move her legs and later described this as an odd crawling sensation in her lower extremities. This episode lasted for five minutes with a full recovery. The patient remained oriented to person and place. The TEE was rescheduled and later performed. The test demonstrated a possible thickened eustacean valve in the right atrium as well as a long, thin and mobile structure attached to the aortic side of the aortic valve leaflets, consistent with a possible fibroelastoma (Figs. 2 & 3). Subsequently, she underwent an elective surgical excision of the mass (Fig. 4) with an uneventful recovery. Surgical pathology confirmed the lesion to be a papillary fibroelastoma (Fig. 5). Patient did not have tumor recurrence or complication from the surgery on one year follow up.

3. DISCUSSION

Although our case was managed surgically as recommended, this stimulated the authors to review cases with surgical contraindications and asymptomatic PFE patients. In the largest comprehensive review of 725 cases, tumor mobility was the only predictor of PFE related death or non fatal embolism [7].

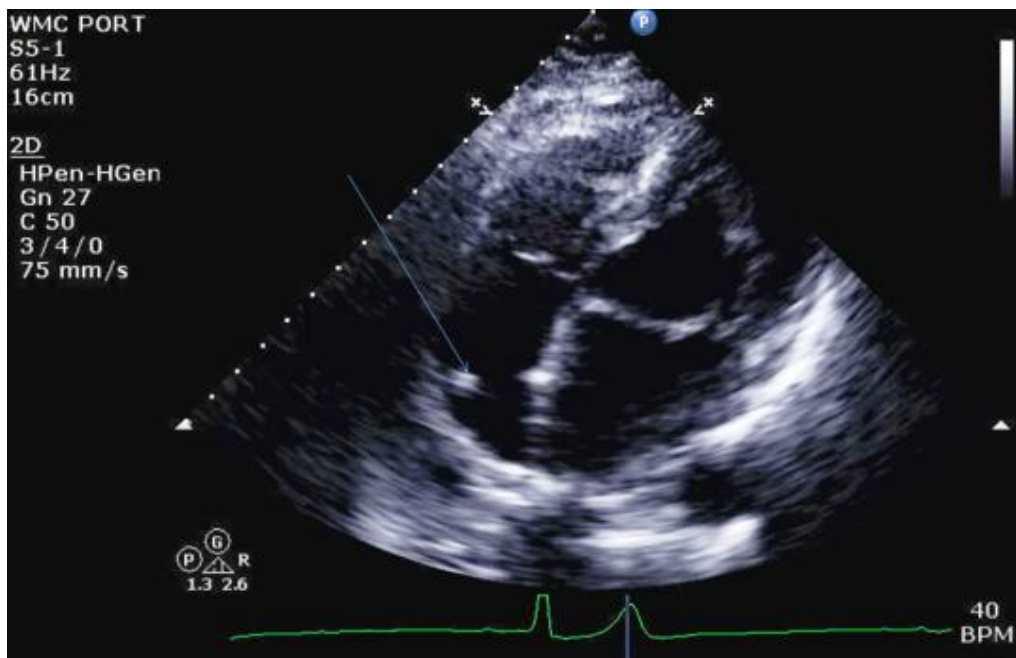


Fig. 1. Transthoracic echocardiogram arrow pointing at echogenic destiny in the right atrium

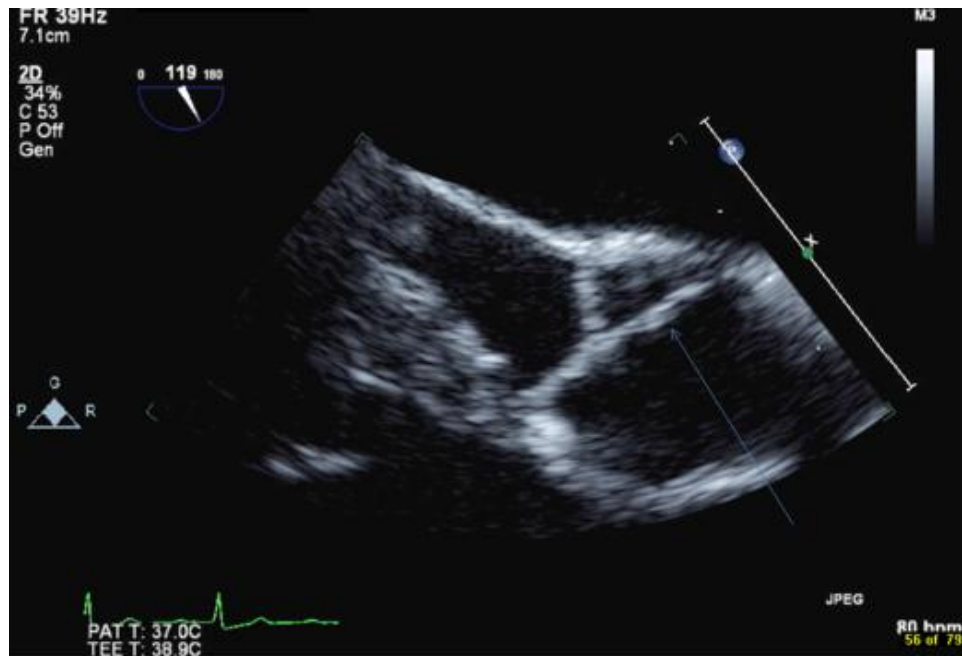

Fig. 2. Transesophageal echocardiogram-LVOT AV view arrow pointing at mobile structure attached to aortic valve papillary fibroelastoma

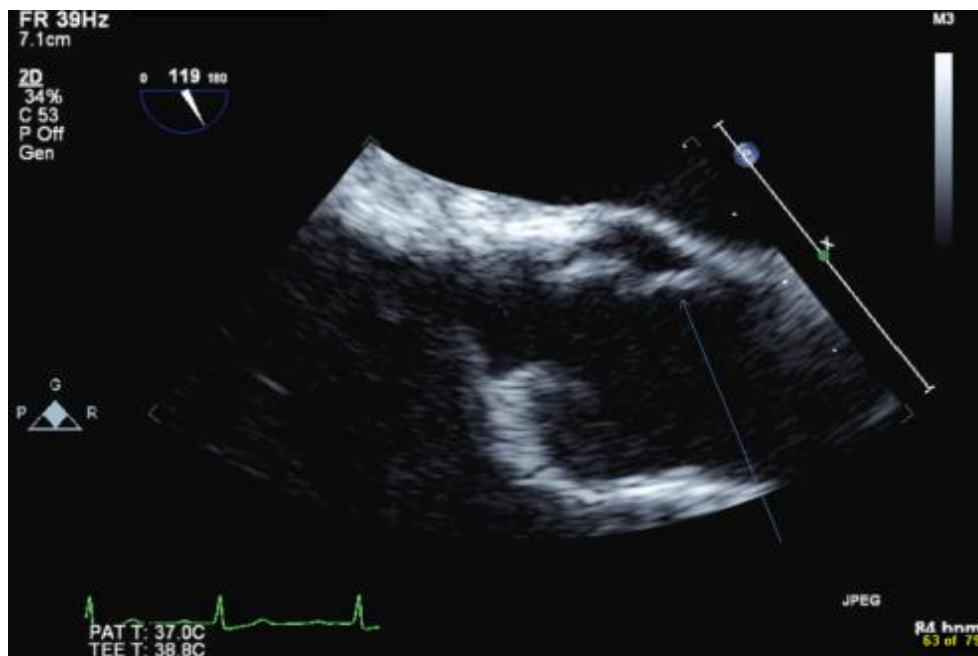


Fig. 3. Transesophageal echocardiogram- LVOT AV view arrow pointing at mobile structure attached to aortic valve papillary fibroelastoma

Enough reviewable data is not available on the management of symptomatic or asymptomatic PFEs with only anticoagulation. To our knowledge, only one case of asymptomatic PFE

with surgical contraindication has been reported, which was managed with oral anticoagulation only and the patient did not experience any symptom or complication related to PFE on four

years of follow up [21]. On review of 109 patients from 2 articles who underwent surgical removal of PFE [10,22] only one (0.91%) patient had surgical mortality who also had concomitant lung resection for bronchiolitis obliterans and no patient had tumor related mortality in 30 days. Out the 88 patient who were followed up for 3 years, none had tumor recurrence or tumor

related death. From the review of data it is suggested that symptomatic patients with surgical contraindications should be treated with long term oral anticoagulation. Asymptomatic patients with mobile PFE should be treated surgically and asymptomatic patients with immobile PFE should be followed up closely and treated if symptoms develop.

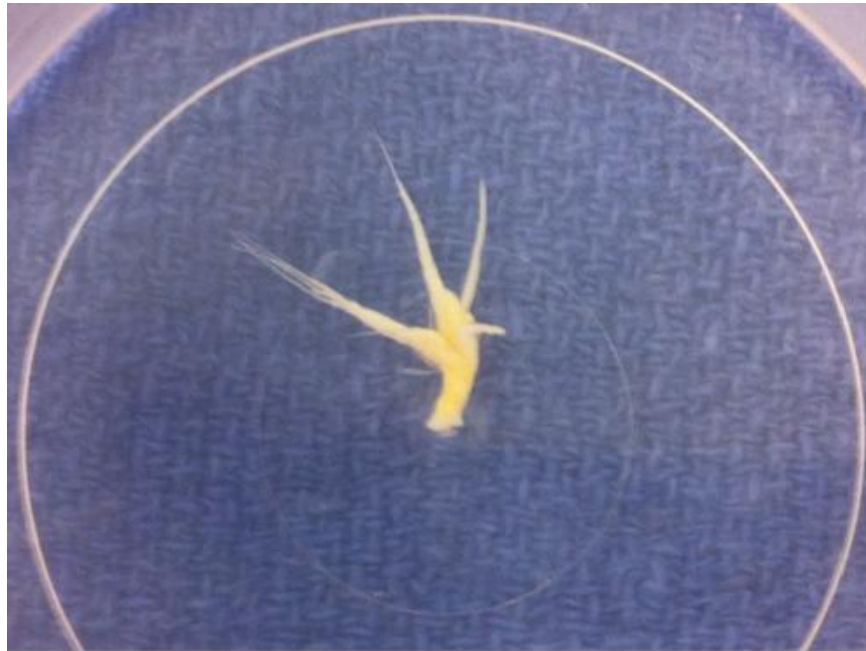

Fig. 4. Surgically excised mass papillary fibroeslastoma

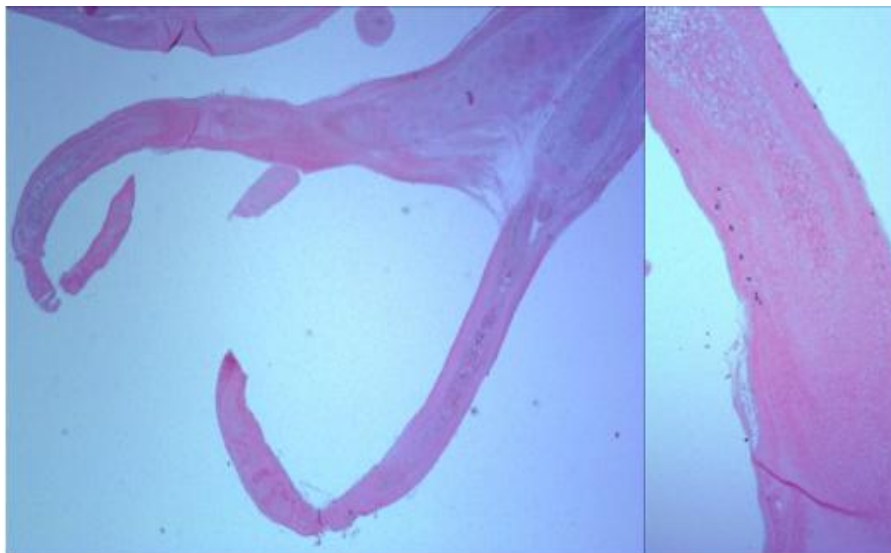


Fig. 5. Histopathology slide consistent with papillary fibroeslastoma

4. CONCLUSION

By reporting this case, authors intend to add to the pool of data. More case reports and clinical trials are needed for the analysis on outcomes of both the management options, which in future would help to lay down the guidelines for management of symptomatic and asymptomatic PFEs.

CONSENT

All authors declare that informed consent was obtained from the patient for publication of this case report and accompanying images.

ETHICAL APPROVAL

It is not applicable.

COMPETING INTERESTS

Authors have declared that no competing interests exist.

REFERENCES

1. Reynen K. Frequency of primary tumors of the heart. *Am J Cardiol*. 1996;77(1):107.
2. Klarich KW, Enriquez-Sarano M, Gura GM, Edwards WD, Tajik AJ, Seward JB. Papillary fibroelastoma: Echocardiographic characteristics for diagnosis and pathologic correlation. *J Am Coll Cardiol*. 1997; 30(3):784-90.
3. Basso C, Valente M, Poletti A, Casarotto D, Thiene G. Surgical pathology of primary cardiac and pericardial tumors. *Eur J Cardiothorac Surg*. 1997;12(5):730-7; discussion 737-8.
4. McAllister HA Jr, Fenoglio JJ Jr. Tumors of the cardiovascular system. In: *Atlas of tumor pathology*, 2nd Series, Fascicle 15. Washington, D.C.: Armed Forces Institute of Pathology; 1978.
5. Sun JP1, Asher CR, Yang XS, Cheng GG, Scalia GM, Massed AG, Griffin BP, Ratliff NB, Stewart WJ, Thomas JD. Clinical and echocardiographic characteristics of papillary fibroelastomas: A retrospective and prospective study in 162 patients. *Circulation*. 2001;103(22):2687-93.
6. Law KB, Phillips KR, Cusimano RJ, Butany J. Multifocal "tapete" papillary fibroelastoma. *J Clin Pathol*. 2009;62(12):1066-70. DOI: 10.1136/jcp.2009.070243.
7. Gowda RM, Khan IA, Nair CK, Mehta NJ, Vasavada BC, Sacchi TJ. Cardiac papillary fibroelastoma: a comprehensive analysis of 725 cases. *Am Heart J*. 2003; 146(3):404-10.
8. Bicer M, Cikirikcioglu M, Pektok E, Müller H, Dettwiler S, Kalangos A. Papillary fibroelastoma of the left atrial wall: A case report. *J Cardiothorac Surg*. 2009;4:28. DOI: 10.1186/1749-8090-4-28.
9. Fine NM, Foley DA, Breen JF, Maleszewski JJ. Multimodality imaging of a giant aortic valve papillary fibroelastoma. *Case Rep Med*. 2013;2013:705101. DOI: 10.1155/2013/705101. Epub 2013 Jul 28.
10. Ngaage DL, Mullany CJ, Daly RC, Dearani JA, Edwards WD, Tazelaar HD, McGregor CG, Orszulak TA, Puga FJ, Schaff HV, Sundt TM 3rd, Zehr KJ. Surgical treatment of cardiac papillary fibroelastoma: A single center experience with eighty-eight patients. *Ann Thorac Surg*. 2005;80(5): 1712-8.
11. Howard RA, Aldea GS, Shapira OM, Kasznica JM, Davidoff R. Papillary fibroelastoma: increasing recognition of a surgical disease. *Ann Thorac Surg*. 1999; 68(5):1881-5.
12. Carpenter JP, Price S, Rubens MB, Sheppard MN, Moat NE, Morgan A, Prasad SK, Mohiaddin RH. Aortic papillary fibroelastoma as an unusual cause of angina: insights from multimodality imaging. *Circ Cardiovasc Imaging*. 2011; 4(2):191-3. DOI: 10.1161/CIRCIMAGING.110.962332.
13. Jha NK, Khouri M, Murphy DM, Salustri A, Khan JA, Saleh MA, Von Canal F, Augustin N. Papillary fibroelastoma of the aortic valve--a case report and literature review. *J Cardiothorac Surg*. 2010;5:84. DOI: 10.1186/1749-8090-5-84.
14. Li A, Azarisman SM, Teo KS, Worthley MI, Sidharta S, Glenie T, Samaraie L, Chua SK, Bailie TJ, Stuklis R, Worthley SG. The innocent bystander: papillary fibroelastoma. *Am J Med*. 2013;126(11): 964-5. DOI: 10.1016/j.amjmed.2013.07.015.
15. Seto T, Takano T, Otsu Y, Terasaki T, Wada Y, Fukui D, Amano J. Cardiac papillary fibroelastoma: Report of three cases. *Ann Thorac Cardiovasc Surg*; 2013. [Epub ahead of print]
16. Grinda JM, Couetil JP, Chauvaud S, D'Attellis N, Berrebi A, Fabiani JN, Deloche

- A, Carpentier A. Cardiac valve papillary fibroelastoma: surgical excision for revealed or potential embolization. J Thorac Cardiovasc Surg. 1999;117(1):106-10.
17. Corrado G, Panisi P, Checcarelli N, Ambrosiani L. An unusual cause of ischemic stroke with successful thrombolysis. J Stroke Cerebrovasc Dis. 2013;22(8):e691-2.
 18. Darvishian F, Farmer P. Papillary fibroelastoma of the heart: report of two cases and review of the literature. Ann Clin Lab Sci. 2001;31(3):291-6.
 19. Shahian DM, Labib SB, Chang G. Cardiac papillary fibroelastoma. Ann Thorac Surg. 1995;59(2):538-41.
 20. Matsushita A, Manabe S, Tabata M, Fukui T, Shimokawa T, Amano J, Takanashi S. Heterogeneous double cardiac tumor: myxoma concomitant with papillary fibroelastoma. J Card Surg. 2010;25(1):35-7.
DOI: 10.1111/j.1540-8191.2009.00937.x.
 21. Mutlu H, Demir IE, Leppo J, Levy WK. Nonsurgical management of a left ventricular pedunculated papillary fibroelastoma: A case report. J Am Soc Echocardiogr. 2008;21(7):877.e4-7.
 22. Ikegami H, Andrei AC, Li Z, McCarthy PM, Malaisrie SC. Papillary fibroelastoma of the aortic valve: analysis of 21 cases, including a presentation with cardiac arrest. Tex Heart Inst J. 2015;42(2):131-5.
DOI: 10.14503/THIJ-14-4262.

© 2015 Joshi et al.; This is an Open Access article distributed under the terms of the Creative Commons Attribution License (<http://creativecommons.org/licenses/by/4.0>), which permits unrestricted use, distribution, and reproduction in any medium, provided the original work is properly cited.

Peer-review history:

The peer review history for this paper can be accessed here:
<http://www.sciencedomain.org/review-history.php?iid=1121&id=12&aid=9355>